

CONTINUING MEDICAL EDUCATION ΣΥΝΕΧΙΖΟΜΕΝΗ ΙΑΤΡΙΚΗ ΕΚΠΑΙΔΕΥΣΗ

Oral Medicine and Pathology Quiz – Case 12

A 28-year-old male was referred from his dentist for further investigation of an asymptomatic expansion of the anterior mandible. The patient reported periodical mild pain in the area for the past 12 months and mild paresthesia of the left side of the lower lip for the last 4 months. Panoramic radiograph revealed a unilocular radiolucency with thin sclerotic border, extending from the right first premolar to the distal aspect of the left second premolar and causing thinning of the lower border of the mandible in the midline area (fig. 1). The left mental foramen was not demonstrated. An open biopsy, under local anesthesia was performed and the histopathological examination revealed a cystic cavity lined by thin epithelium with a corrugated parakeratotic surface and a palisaded basal cell layer, devoid of rete ridges (fig. 2). The involved teeth were preoperatively treated with root canal therapies and the cyst was completely surgically excised, under local anesthesia, after identification, dissection and preservation of the left mental nerve. No clinical and radiological findings of recurrence were noticed 15 months postoperatively.

Comment

Odontogenic keratocyst (OKC) is a developmental odontogenic cyst that exhibits a locally aggressive behavior and a significant recurrence rate. It is believed to arise from remnants of the dental lamina epithelium. Furthermore, there is evidence suggesting that the pathogenetic mechanism of OKC is different from the other odontogenic cysts and involves molecular alterations, most commonly

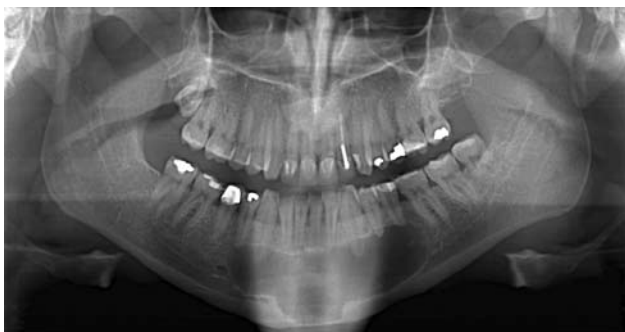

Figure 1

seen in neoplasms. The 2005 WHO classification of odontogenic tumors suggested the new term keratocystic odontogenic tumor to denote its purported cystic neoplastic nature. This term is not widely accepted and may have caused confusion among the scientific community.

OKCs can be found in patients of any age, but the majority (around 60%) are diagnosed between the ages of 10 to 40 years. There is a slight predilection for men. OKCs can occur anywhere in the jaws. Nevertheless, 65–75% of the cases involve the mandible with a marked tendency for the molar/ramus area. OKCs tend to grow in an anteroposterior direction, without obvious bone expansion. Patients with multiple lesions should be evaluated for the nevoid basal cell carcinoma (Gorlin) syndrome. These patients develop several skeletal and soft tissue deformities, recurrent OKCs involving both jaws at a young age as well as multiple basal cell carcinomas of the skin.

Radiographically, OKC presents as a well-circumscribed radiolucency with smooth radiopaque margins. It may be unilocular or multilocular and may also have a relationship with the crown of an impacted tooth. Moreover, the term primordial cyst was used

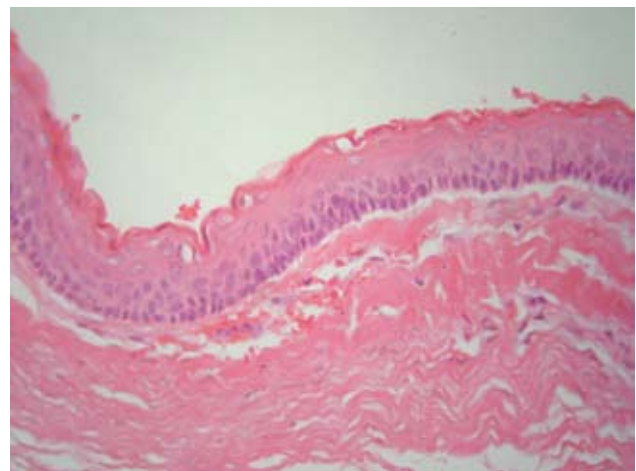


Figure 2

ARCHIVES OF HELLENIC MEDICINE 2010, 27(2):283–284
ΑΡΧΕΙΑ ΕΛΛΗΝΙΚΗΣ ΙΑΤΡΙΚΗΣ 2010, 27(2):283–284

**N.G. Nikitakis,
G. Kamperos,
V. Petsinis,
A. Sklavounou-Andrikopoulou**

*Department of Oral Medicine and
Pathology, School of Dentistry, National
and Kapodistrian University of Athens,
Athens, Greece*

in the past to describe cystic lesions arising in the place where a tooth should have developed. These lesions almost always show the distinctive histopathological features of OKC and as such should be recognized.

Microscopically, the cystic epithelium is thin (6–10 cell lines), devoid of rete ridges, with a wavy parakeratotic lining. The basal cell layer is composed of a palisaded layer of cuboidal or columnar cells. The cystic wall is friable typically without an inflammatory infiltrate. Daughter cysts are commonly found within the cystic wall. The typical histologic features may be altered in case of inflammatory changes.

Radiographic differential diagnosis involves several cysts and tumors, odontogenic or not, which is modified according to the unilocular or multilocular presentation of any given lesion. However, the histopathological features of OKC are distinctive.

OKCs are treated by enucleation, curettage and ostectomy of the bony walls with a bone bur; yet, the friable nature of the cystic wall makes it difficult to remove it in one piece. The remaining

cystic fragments or the daughter cysts in the cystic wall give rise to recurrences in a significant proportion of the cases, which varies from 5–62% in different studies. Cauterization with Carnoy's solution may reduce recurrence, while larger cysts may be treated with decompression or marsupialization followed by enucleation of the reduced lesion. Large lesions exhibiting multiple recurrences may necessitate a more radical surgical approach. Long-term follow-up is warranted. Except for the tendency for recurrences, the overall prognosis of OKC is good, although rare examples of malignant transformation of the cystic epithelium have been reported.

Corresponding author:

N.G. Nikitakis, Department of Oral Pathology and Medicine, School of Dentistry, National and Kapodistrian University of Athens, 2 Thivon street, GR-115 27 Athens, Greece, tel: +30 210 74 61 003, fax: +30 210 7461220
e-mail: nnikitakis1@yahoo.com