

CONTINUING MEDICAL EDUCATION ΣΥΝΕΧΙΖΟΜΕΝΗ ΙΑΤΡΙΚΗ ΕΚΠΑΙΔΕΥΣΗ

Thoracic Surgery Quiz – Case 10

A 76-year-old male was presented for the complaint of intermittent, non-productive cough which had become continuous (24 hours a day) and disabling. The patient had referred previously to a department of internal medicine for outpatients. The initial diagnosis of asthma led to a treatment strategy that included inhaled bronchodilators and corticosteroids. Patient's condition showed no significant improvement. At the time of presentation in our department he had no documented evidence of repeated lower respiratory chest infections. There were no palpable lymph nodes. The clinical examination of the chest, head and neck was unremarkable. Past surgical history included abdominal aorta aneurysm repair. The routine laboratory tests were within normal limits. Arterial blood gas analysis on admission day was PO₂: 88, PCO₂: 38, pH: 7.39, SO₂: 97.9%, HCO₃: 23.4 and spirometry values (FEV1 92.9, FVC 95, and FEV1/FVC 96) were within normal limits. On the initial work up, a chest x-ray (face/profile), showed nothing of significance. Chest CT scan revealed a large esophageal diverticulum, measuring approximately 3×4×4cm (fig. 1). Barium esophagram further defined the presence of the Zenker's diverticulum (fig. 2). Open surgical approach was the method of treatment. The diverticulum was resected via a left incision over the anterior border of the sternocleidomastoid muscle (figures 3, 4). Patient was allowed to resume oral feeding at the second postoperative day and was released from the hospital 5 days after the operation. He remained without symptoms (cough) 4 weeks postoperatively.

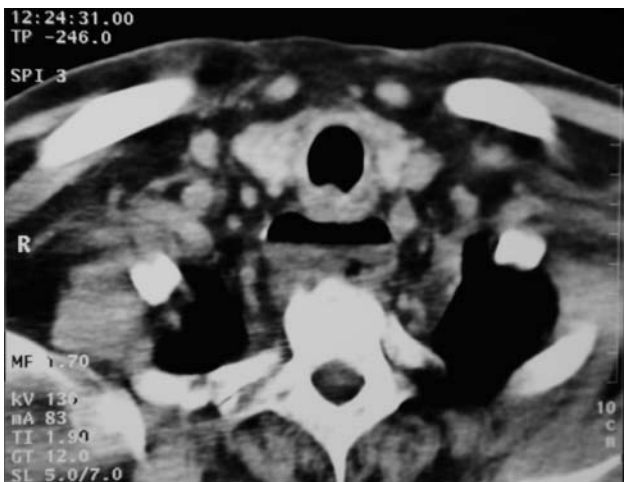

Figure 1.

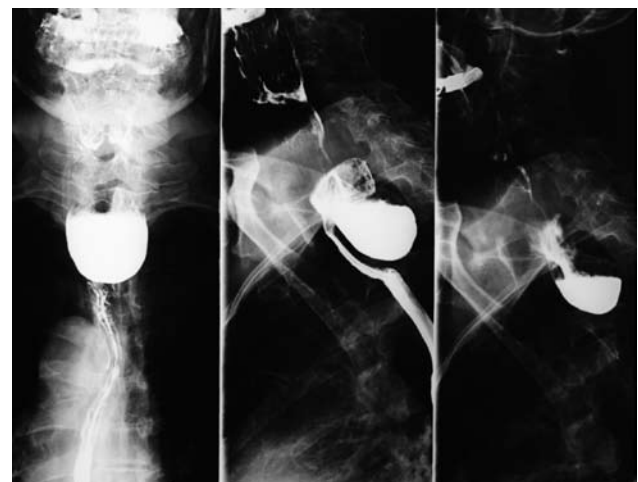


Figure 2.

ARCHIVES OF HELLENIC MEDICINE 2010, 27(3):568–569
ΑΡΧΕΙΑ ΕΛΛΗΝΙΚΗΣ ΙΑΤΡΙΚΗΣ 2010, 27(3):568–569

E.D. Spartalis,¹
P. Paraskeva,¹
P. Katsaronis,¹
A. Smyrnis,¹
G. Karagiouzis,¹
Ch. Markakis,³
Ch. Mpasagiannis,²
P. Tomos¹

¹Second Department of Propedeutic Surgery,

²First Department of Propedeutic Pathology, National and Kapodistrian University of Athens, Medical School, "Laiko" General Hospital of Athens, Athens

³First Department of Surgery, "Tzaneio" General Hospital of Pireus, Pireus, Greece

Comment

Most Zenker's diverticula are small, often undetected and asymptomatic. In cases of a symptomatic diverticulum, patients usually complain of dysphagia, regurgitation, aspiration, mucus in the throat, weight loss, halitosis, and intermittent obstruction of the esophageal lumen. Cough has not been commonly reported. This case is presented to illustrate that these lesions can be a cause of significant pulmonary symptoms and should be considered as a potential cause of persistent cough.

Zenker's diverticulum is defined as a blow out of the mucosa through a so-called locus minoris resistentiae on the posterior wall

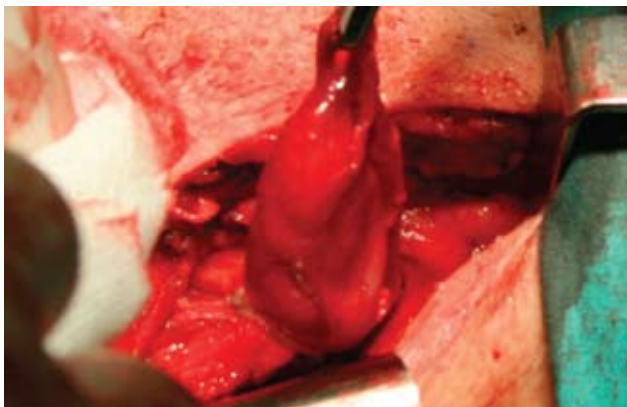


Figure 3.

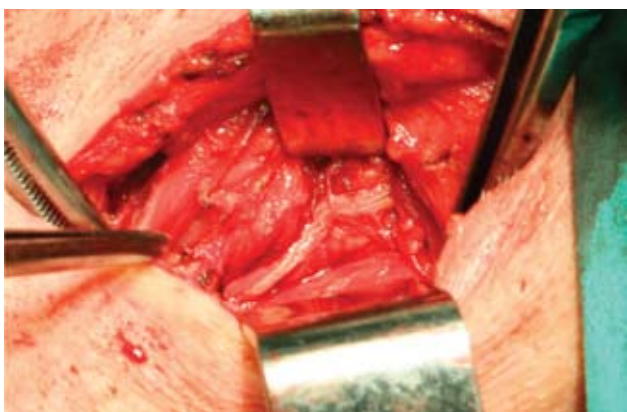


Figure 4.

at the transition zone between the hypopharynx and the esophagus (Killian's triangle).

Pharyngo-esophageal diverticulum was described for the first time as a pathologic entity by Ludlow in 1679. However, it was Zenker who gave his name to this condition through his publication in 1877 reporting a series of 27 patients. Already at that time Zenker presumed the pouch being the consequence of "forces within the lumen acting against a restriction" a hypothesis which is close to modern understanding of pathogenesis indeed and remarkable since both endoscopy and X-ray had yet to be invented. However, the mechanistic compression theory as a cause of symptoms would prevail until far into the 20th century dominating the therapeutic strategy as well (diverticulectomy). Only during the last decennia of the 20th century, thanks to the new developments in imaging, endoscopy, manometry and manofluography, better insights into the pathogenesis of Zenker's diverticulum came through resulting in fundamental changes in the therapeutic strategy (myotomy of the cricopharyngeal muscle).

For decades the open cervical approach was the treatment of choice for Zenker's diverticulum.

A minority of surgeons, mostly ENT specialists, had applied an

endoluminal approach. By introducing a fixed rigid esophagoscope the common wall between the esophagus and the pouch (the so-called cricopharyngeal bar) could be divided. Whilst initially using scissors or electrocoagulation over time CO₂ laser or laser beam as well as magnifying devices were introduced in order to refine the technique. However, this technique never really became popular mainly because of the fear for perforation and subsequent risk of mediastinitis.

More recently the open approach as described in this chapter has been challenged by the videoendoscopic stapled diverticulectomy or endoscopic myotomy. The latter now being performed under sedation and on an ambulatory basis.

The claimed advantages are no external trauma without visible scar and shorter hospital stay.

It appears, however, that the videoendoscopic approach results more frequently in a need for re-intervention and in a clear and higher incidence of recurrence or insufficient control of symptoms. The incidence of patients being totally asymptomatic is clearly higher when using an open approach incorporating a myotomy as compared to the videoendoscopic approach which is well reflected by two available comparative studies.

As to the flexible endoscope approach, it appears that this technique carries a higher risk for perforation resulting in a lower clinical remission rate as compared to the surgical videoendoscopic stapled diverticulectomy and a fortiori the open approach as described in this chapter.

Therefore, the open surgical approach remains the preferred method of treatment. Endoscopic techniques may be the preferred method in those occasional patients who present with contraindications for general anesthesia or open surgery.

References

1. ISHIOKA S, SAKAI P, MALUF F, MELO JM. Endoscopic incision of Zenker's diverticula. *Endoscopy* 1995, 27:433-437
2. GUTSCHOW CA, HAMOIR M, ROMBAUX P, OTTE JB, GONCETTE L, COLLARD JM. Management of pharyngoesophageal (Zenker's) diverticulum: Which technique? *Ann Thorac Surg* 2002, 74:1677-1682
3. RIZZETTO C, ZANINOTTO G, COSTANTINI M, BOTTIN R, FINOTTI E, ZANATTA L ET AL. Zenker's diverticula: Feasibility of a tailored approach based on diverticulum size. *J Gastrointest Surg* 2008, 12:2057-2064; discussion 2064-2065
4. COSTAMAGNA G, IACOPINI F, TRINGALI A, MARCHESE M, SPADA C, FAMILIARI P ET AL. Flexible endoscopic Zenker's diverticulotomy: Cap-assisted technique vs diverticuloscope-assisted technique. *Endoscopy* 2007, 39:146-152

Corresponding author:

P. Paraskeva, "Laiko" General Hospital of Athens, 17 Agiou Thoma street, GR-115 27 Athens, Greece
 e-mail: noraparaskeva@hotmail.com

Diagnosis: Zenker's diverticulum

