

CONTINUING MEDICAL EDUCATION ΣΥΝΕΧΙΖΟΜΕΝΗ ΙΑΤΡΙΚΗ ΕΚΠΑΙΔΕΥΣΗ

Hematology Quiz – Case 22

A 63-year-old man presented with a 7-day history of low-grade fevers, night sweating, fatigue and abdominal discomfort. One year previously he was diagnosed with normal-karyotype acute myelogenous leukemia of myelomonocytic subtype (AML M4) and entered complete remission with standard induction and consolidation chemotherapy. On admission, blood pressure was 115/67 mmHg, pulse 110 bpm, temperature 37.9 °C and oxymetry 96%. Physical examination was remarkable for the presence of splenomegaly (4 cm below costal margin) and hepatomegaly (liver span 15 cm). Laboratory investigations revealed hemoglobin 8.1 g/dL, leucocytes 12,000/ μ L, neutrophils 950/ μ L, platelets 80,000/ μ L, normal liver and kidney function, lactate dehydrogenase 875 IU/L, uric acid 8.2 mg/dL and C-reactive protein 10 mg/dL. Peripheral blood film showed 32% immature cells (blasts and promonocytes), 28% monocytes and dysplastic changes. Chest radiograph was normal and blood and urine cultures gave negative results. Bone marrow aspiration revealed 36% infiltration by immature cells (myeloblasts and promonocytes), 27% monocytes, dysplastic changes and an unexpected finding. Photomicrographs of bone marrow aspirate smears are shown in figures 1, 2 and 3.

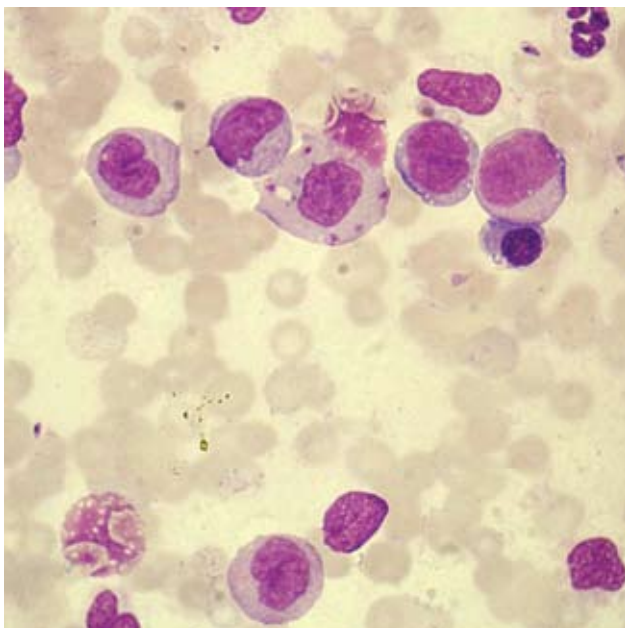


Figure 1

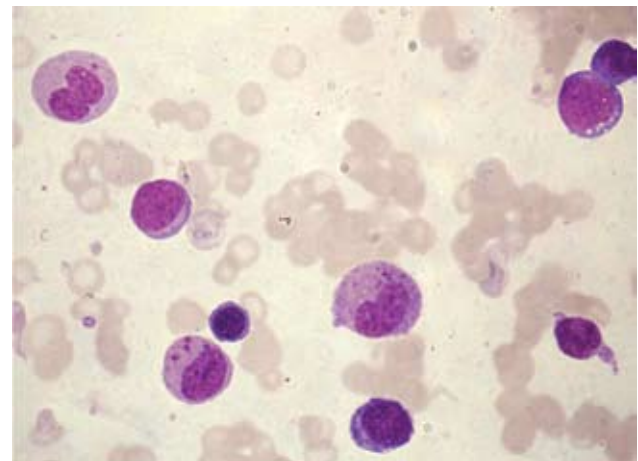


Figure 2

ARCHIVES OF HELLENIC MEDICINE 2011, 28(1):132–133
ΑΡΧΕΙΑ ΕΛΛΗΝΙΚΗΣ ΙΑΤΡΙΚΗΣ 2011, 28(1):132–133

**K. Liapis,
J. Apostolidis,
S. Delimpasi,
F. Panitsas,
F. Michelis,
A. Komitopoulou,
I. Tzannou,
S. Gigantes,
M. Pagoni,
M. Mpakiri,
Th. Karmiris,
N. Harhalakis**

*Department of Hematology and
Lymphoma, Unit of Bone Marrow
Transplantation, "Evangelismos"
General Hospital, Athens, Greece*

Comment

*The figures portray the presence of myeloblasts, promonocytes and monocytes; in addition, occasional monocytes and promonocytes contain endocytosed amastigotes of *Leishmania d. infantum*. Two naked Leishman-Donovan bodies also lie scattered about the field in figure 1. The diagnosis of relapsed acute myelomonocytic leukemia and visceral leishmaniasis (VL) was confirmed by flow cytometric analysis and detection of antileishmanial antibodies, respectively. The marrow blasts displayed positive immunophenotyping for CD34, CD117, HLA-DR, CD33, CD13, CD15, CD14, CD4, CD64 and cytogenetic analysis showed normal chromosomes.*

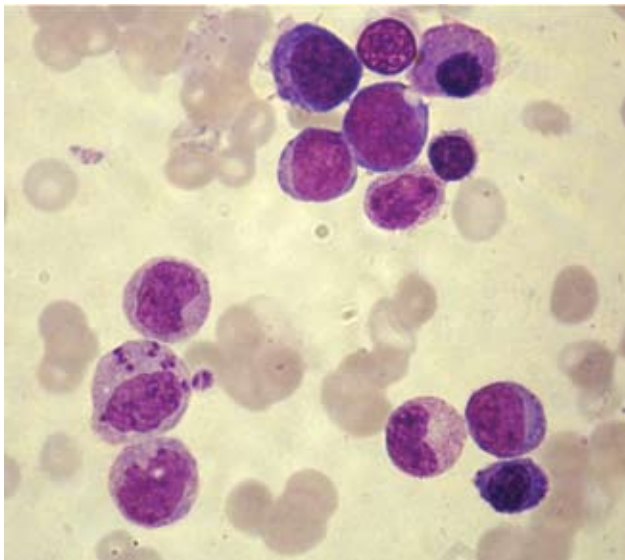


Figure 3

The patient was treated with liposomal amphotericin and salvage chemotherapy.

Visceral leishmaniasis has been recognized as a possible opportunistic infection for the immunocompromised population. Visceral leishmaniasis has rarely been reported in acute myeloid

leukemia (AML) and most case reports originate from countries where the disease is endemic or prevalent. Leukemic promonocytes and monocytes, despite leukemic transformation, may show partial preservation of their functional activity. It has been found that leukemic monocytes are subnormal with respect to Fcγ and C3b surface receptors; however, pinocytosis is not seriously hampered and endocytosis of bacteria or parasites may be observed.

References

1. SAH SP, RIJAL S, BHADANI PP, RANI S, KOIRALA S. Visceral leishmaniasis in two cases of leukemia. *Southeast Asian J Trop Med Public Health* 2002, 33:25–27
2. VAN FURTH R, VAN ZWETTL. Cytochemical, functional, and proliferative characteristics of promonocytes and monocytes from patients with monocytic leukemia. *Blood* 1983, 62:298–304
3. BAIN BJ. *Leukemia diagnosis*. 3rd ed. Blackwell Publ, Oxford, 2003:90–97

Corresponding author:

K. Liapis, Department of Hematology and Lymphoma, Unit of Bone Marrow Transplantation, “Evangelismos” General Hospital, 45–47 Ipsilantou street, GR-106 76 Athens, Greece, tel.: +30 210 72 01 131, fax: +30 210 7201131
e-mail: kosliapis@hotmail.com