

CONTINUING MEDICAL EDUCATION ΣΥΝΕΧΙΖΟΜΕΝΗ ΙΑΤΡΙΚΗ ΕΚΠΑΙΔΕΥΣΗ

Pediatric Radiology Quiz – Case 18

An 8-year-old child was referred to our outpatient orthopedic department due to chronic left shoulder pain. Its parents mentioned that the symptoms started three months ago. During that period they visited an orthopedic at his private practice that referred the child for a shoulder magnetic resonance imaging (MRI), which showed no pathological findings; however, symptoms continued and deteriorated, so they visited our hospital. Physical examination revealed mild incapacitating and limitation of the shoulder's range of motion, mild torticollis and irritation when rotating its neck without neurological deficits. Blood tests were normal. Conventional radiographs showed flattening (vertebra plana) of T₁ vertebral body with preservation of the intervertebral spaces (fig. 1a). Computed tomography (CT) showed complete compression of the T₁ vertebral body, perivertebral soft tissue protruding in the spinal canal and end plate sclerosis of the adjacent vertebrae, without destructive changes (fig. 1b, fig. 2a, b). CT guided biopsy was performed that confirmed the diagnosis.

Comment

Vertebra plana or pancake is a condition in which the vertebra body has lost almost its entire height and is reduced to a sclerotic disk. It can occur with a variety of settings including trauma, osteoporosis, eosinophilic granuloma, osteogenesis imperfecta, leukemia, vertebral metastases, multiple myeloma, lymphoma, osteomyelitis, spinal tuberculosis and spinal hemangioma.

Eosinophilic granuloma (EG) is a benign and solitary bony

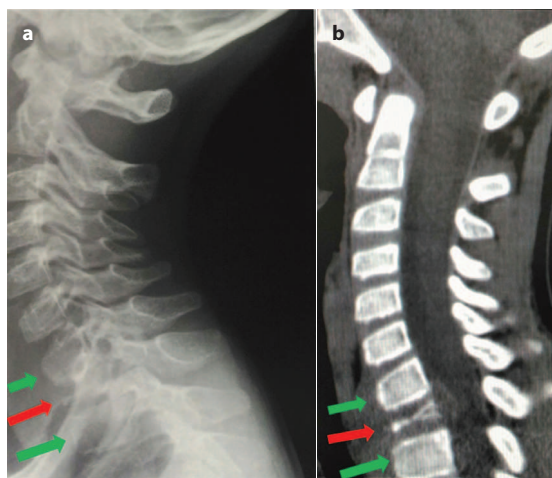


Figure 1a, b. Cervical spine X-ray and computed tomography (CT) (sagittal view) that reveals T₁ vertebra flattening (red arrow). Notice the normal height of the neighbouring C₇ and T₂ vertebrae (green arrows).

ARCHIVES OF HELLENIC MEDICINE 2016, 33(5):711
ΑΡΧΕΙΑ ΕΛΛΗΝΙΚΗΣ ΙΑΤΡΙΚΗΣ 2016, 33(5):711

T.N. Spyridopoulos,^{1,2}
A. Larda,¹
K. Tsilikas,¹
A. Stratigopoulou,¹
S. Stathopoulou¹

¹Department of Radiology, General Children's Hospital, Palea Penteli, Attiki
²EchoHealth Pediatric and Adult Ultrasound Clinic, Athens, Greece

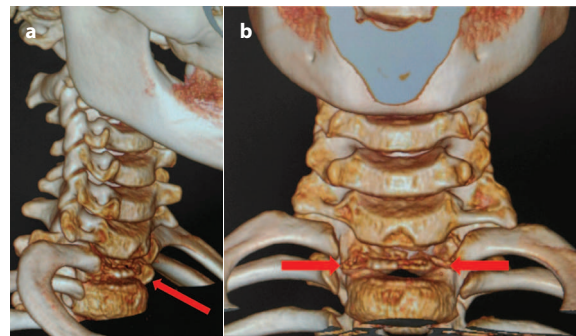


Figure 2a, b. 3-D computed tomography (CT) reconstructed images (oblique and coronal view) showing the T₁ vertebra flattening (red arrows), at the level of first pair of thoracic ribs.

lesion of unknown etiology. EG, Letterer-Siwe and Hand-Schüller-Christian disease represent a spectrum of the same disease entity, known as Langerhans cell granulomatosis or Histiocytosis X. EG predominantly affects the skull, the ribs, the pelvis, the mandible, and the metaphyses of other long bones. Although rare, EG should always be included in the differential diagnosis for osteolytic spine lesions in children population.

References

- DENARO L, LONGO UG, PAPALIA R, Di MARTINO A, MAFFULLI N, DENARO V. Eosinophilic granuloma of the pediatric cervical spine. *Spine (Phila Pa 1976)* 2008, 33:E936–E941
- CHEN SY, CHAO SC, KAO TH, SHEN CC, TSOU HK. Surgical treatment using mesh cage and plate fixation in a 9-year-old child with solitary histiocytosis lesion in the cervical spine. *Eur J Pediatr Surg* 2011, 21:189–191

Corresponding author:

T.N. Spyridopoulos, Department of Radiology, General Children's Hospital, Palea Penteli, Attiki and EchoHealth Pediatric and Adult Ultrasound Clinic, Athens, Greece, tel.: +30 2107237476,
e-mail: t.spyridopoulos@echohealth.gr

Diagnosis: Eosinophilic granuloma