

CONTINUING MEDICAL EDUCATION ΣΥΝΕΧΙΖΟΜΕΝΗ ΙΑΤΡΙΚΗ ΕΚΠΑΙΔΕΥΣΗ

Vascular Diseases Quiz – Case 41

A 68-year old patient with chronic kidney injury and on dialysis since 15 years had an arterio-venous fistulae (AVF) failure on his left arm. The patient has been having multiple AVF and graft dialysis accesses performed since he begun dialysis. All autogenous options have now failed and both distal subclavian arteries are thrombosed after AV grafts have been occluded and excised. Both femoral veins are intact and a dialysis catheter is placed in the right femoral artery. Both jugular veins have been used in the past for temporary dialysis catheters.

What are the available option for dialysis vascular access?

1. Brachio-basilic AVF on either arm
2. AV graft from femoral vein to femoral artery
3. 'Necklace' graft (subclavian artery to contralateral subclavian vein along the anterior chest wall)
4. AV graft from subclavian artery to ipsilateral subclavian vein

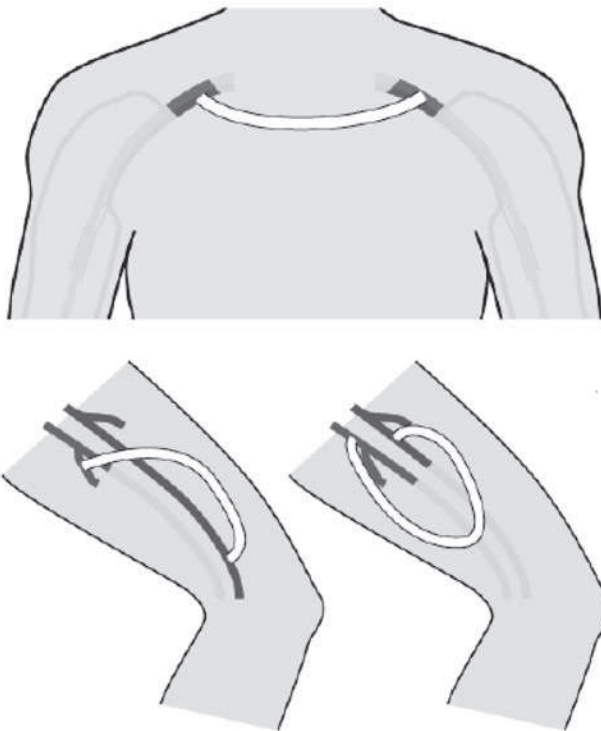


Figure 1

ARCHIVES OF HELLENIC MEDICINE 2017, 34(3):430
ΑΡΧΕΙΑ ΕΛΛΗΝΙΚΗΣ ΙΑΤΡΙΚΗΣ 2017, 34(3):430

**N. Patelis,
D. Schizas,
C. Klonaris**

First Department of Surgery, Vascular Unit, Medical School, National & Kapodistrian University of Athens, Laikon General Hospital, Athens, Greece

5. All answers are correct except No 1
6. All answers are correct.

Comment

Vascular access (VA) for hemodialysis is necessary to perform an efficient dialysis procedure. There are general rules that apply in creating well-functioning VAs and simultaneously maintain any possible vascular sites for future VA needs. The rule states that first VA is performed as distally: forearm (radio-cephalic or distal AVF), elbow (brachio-cephalic or proximal AVF), arm (brachial-basilic AVF with transposition or proximal AVF). In our patient, both forearms and upper arms are not available by the already failed AVFs and excluded by the thrombosed subclavian veins. Jugular veins might be patent, but recurrent dialysis catheter placements have stenosed or occluded the vessels. Lower limb VAs has a poor long-term patency and femoral VAs are prone to infections. In this patient, left femoral VA is an option if no other VA site is available. Necklace and subclavian AV grafts are more complicated options.

References

1. SANTORO D, BENEDETTO F, MONDELLO P, PIPITÒ N, BARILLA D, SPINELLI F ET AL. Vascular access for hemodialysis: current perspectives. *Int J Nephrol Renovasc Dis* 2014, 7:281–294
2. CARLI T, PINTAR T, GODNOV U. Screening needs and expectations of patients with vascular access due to chronic hemodialysis. *Journal of Health Sciences* 2016, 6:184–1877
3. PRICE AJ, FIDELMAN N, WILSON MW, KERLAN RK. Percutaneous interventions in failing “necklace” hemodialysis grafts: Long-Term Outcomes. *J Vasc Intervent Radiol* 2014, 25:199–205

Corresponding author:

C. Klonaris, First Department of Surgery, Vascular Division, Medical School, National and Kapodistrian University of Athens, “Laikon” General Hospital, 115 27 Athens, Greece
e-mail: chris_klonaris@yahoo.com

Answers: All answers are correct except No 1