

## CASE REPORT ΕΝΔΙΑΦΕΡΟΥΣΑ ΠΕΡΙΠΤΩΣΗ

# Anemia associated with autoimmune liver disease in a middle-aged female

Autoimmune hepatitis (AIH) and primary biliary cholangitis (PBC) can coexist as a variant syndrome of autoimmune liver disease. The case is reported of a 49-year-old woman with anemia and ascites, in whom laboratory tests and liver biopsy revealed chronic autoimmune liver disease as the cause of her anemia. This case adds to a list of several case reports of a variant syndrome of autoimmune liver disease and anemia.

ARCHIVES OF HELLENIC MEDICINE 2019, 36(1):114–116  
ΑΡΧΕΙΑ ΕΛΛΗΝΙΚΗΣ ΙΑΤΡΙΚΗΣ 2019, 36(1):114–116

N.D. Karakousis,<sup>1</sup>  
V. Kolonia,<sup>1</sup>  
A.D. Saltamavros,<sup>1</sup>  
P. Ntellas,<sup>2</sup>  
K. Kaligeros<sup>1</sup>

<sup>1</sup>Second Department of Internal Medicine, "Sismanogleio" General Hospital, Athens

<sup>2</sup>Postgraduate Programme, Clinical Applications of Molecular Medicine, Department of Immunology, Faculty of Medicine, University of Thessaly, Larissa, Greece

Αναιμία που σχετίζεται  
με αυτοάνοση ηπατοπάθεια  
σε γυναίκα μέσης ηλικίας

Περίληψη στο τέλος του άρθρου

### Key words

Autoimmune hemolytic anemia (AIHA)  
Autoimmune hepatitis (AIH)  
Primary biliary cholangitis (PBC)  
Ursodeoxycholic acid (UDCA)  
Variant syndrome

Submitted 15.3.2018

Accepted 23.3.2018

Primary biliary cholangitis (PBC), also known as primary biliary cirrhosis, is a chronic, slowly progressive autoimmune liver disease causing cholestasis. Small intrahepatic bile ducts sustain damage that may lead to fibrosis and liver failure within a few years. Pruritus and fatigue are usually the first symptoms.<sup>1</sup> The diagnosis of PBC is based on the clinical findings and liver function tests. Seropositivity for antimitochondrial antibodies (AMA) and raised serum levels of alkaline phosphatase (ALP), combined with the liver biopsy findings, are considered diagnostic.<sup>1</sup>

Autoimmune hepatitis (AIH) is also a chronic autoimmune liver disease, which affects women more often than men and may be completely asymptomatic, although in rare cases it presents with acute hepatic failure. The initial symptoms include fatigue, muscle aches, jaundice and fever as a result of liver inflammation.<sup>1</sup> These symptoms support

the diagnosis of AIH, along with the laboratory findings, specifically, raised serum levels of serum aminotransferase (SGOT-SGPT) and immunoglobulins, primarily IgG, hyperbilirubinemia, and normal or slightly elevated serum ALP.<sup>1</sup> Other laboratory findings include seropositivity for antinuclear antibodies (ANA), smooth muscle antibodies (SMA), perinuclear anti-neutrophil cytoplasmic antibodies (pANCA), liver-kidney microsomal type 1 antibodies (LKM-1) and antibodies against soluble liver antigen/liver pancreas antigen (SLA/LP).<sup>1</sup>

Overlap or variant syndrome of autoimmune liver disease is a term used to describe the presence of both autoimmune liver diseases. Variant syndrome, especially the PBC type, may be associated with other autoimmune diseases, such as autoimmune hemolytic anemia (AIHA) and immune thrombocytopenic purpura (ITP), also known as Evans syndrome.<sup>2-7</sup>

## CASE PRESENTATION

A 49-year-old woman was admitted, initially to the hematology department, for investigation of anemia and weight loss of about 6 kg over the preceding 12 months. A few days before admission, she reported development of abdominal bloating, pruritus and fever with a body temperature of 37.5 °C. She had a medical history of hypothyroidism.

On initial examination the patient's vital signs were normal. Her abdomen was soft, without tenderness and with normal abdominal sounds, but percussion revealed shifting dullness. The rest of the physical examination was normal. Abdominal ultrasound (US) revealed ascites and several lymph nodes, under 2 cm in size near the portal area, without biliary duct dilatation.

Blood tests revealed normocytic anemia (Hb 9.1 g/dL, MCV 94.1 fL) with a normal peripheral blood smear, platelets  $152 \times 10^3/\mu\text{L}$  and white blood cell count (WBC)  $3,430 \times 10^3/\mu\text{L}$ . The erythrocyte sedimentation rate (ESR) was high (125 mm/1 hour). The liver function tests were normal, apart from slightly raised ALP (300 IU/L) and serum gamma-glutamyl transferase ( $\gamma\text{GT}$ ) (110 IU/L).

The glucose-6-phosphate dehydrogenase level (G6PD) was normal. The direct Coombs test was positive (++) . Bone marrow biopsy did not confirm any specific diagnosis.

After development of severe pruritus, increasing ascitic fluid and deterioration of the serum liver function tests, the patient was evaluated by a hepatologist. Abdominal computed tomography (CT) scan revealed hepatosplenomegaly, massive ascites and gallstones in the gallbladder without inflammation (fig. 1). Gastroscopy showed mild gastritis.

Hypergammaglobulinemia with an increase of IgG (5,930 mg/dL) and IgM (289 mg/dL) levels was detected and ANA, AMA (M2), SMA, pANCA were elevated (tab. 1). Anti-TPO antibody was 217.1 IU/mL. Screening tests for hepatotropic and other viruses were negative. The serum ascites albumin gradient (SAAG) identified the presence of portal hypertension.

Because of the gallstones detected in the gallbladder, cholecystectomy was performed, at which time a liver biopsy was taken, which showed histopathology indicative of variant syndrome of autoimmune liver disease, PBC type, affecting mainly small biliary ducts, rather than hepatic cells. Ursodeoxycholic acid (UDCA) was administered (250 mg $\times$ 4/day, *per os*), in order to decelerate the progression of liver fibrosis. Because of the portal hypertension and ascites, spironolactone 25 mg  $\frac{1}{2}\times$ 1/day *per os* and furosemide 40 mg  $\frac{1}{2}\times$ 1/day *per os* were also prescribed. After 3 weeks of treatment, the hematocrit rose to 35%. Addition of fibrates to the treatment regime remain under consideration.

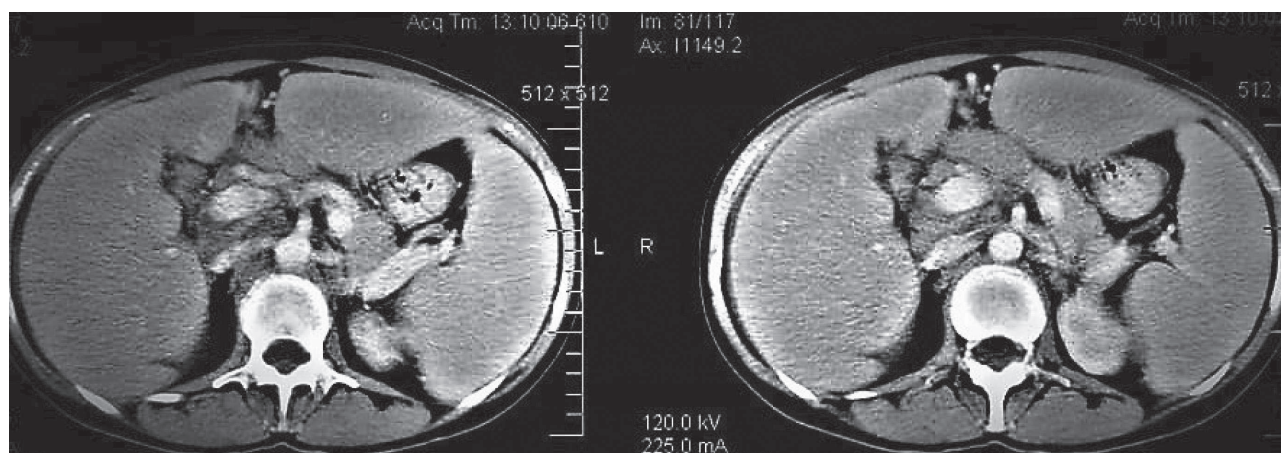
## DISCUSSION

Various reports have associated autoimmune liver disease syndromes, especially PBC type, with anemia.<sup>2-7</sup> A wide range of AIH-PBC variant syndromes can be associated with extrahepatic autoimmune diseases.<sup>2</sup> In a series of 71 patients with AIH-PBC, 31 (43.65%) had extrahepatic autoimmune diseases, including AIHA.<sup>2</sup> Report was made of a 53-year-old patient with PBC-AIH (PBC type) with AIHA and ITP (Evans syndrome).<sup>3</sup> With autoimmune liver disease treatment, her Hb and platelets increased rapidly within a few days.<sup>3</sup> Other reports document AIHA as a complication

**Table 1.** Autoantibodies test results in a 49-year-old female, suggestive of variant syndrome of autoimmune liver disease.

ANA (NEG <1/80)	AMA (NEG <1/20)	SMA (NEG <1/20)	pANCA	M2 fraction (ref. range <25 units)
> 1:2560	>1/160	>1:160	1/160 (positive)	162.7 units

ANA: Antinuclear antibodies, AMA: Antimitochondrial antibodies, SMA: Smooth muscle antibodies, pANCA; Perinuclear anti-neutrophil cytoplasmic antibodies



**Figure 1.** Abdominal computed tomography (CT) scan in a 49-year-old female with variant syndrome of autoimmune liver disease, showing enlarged liver and spleen, massive ascites and gallstones in the gallbladder without inflammation.

of PBC.<sup>4-6</sup> Of particular note is the case report of 3 patients who had undergone successful liver transplantation for PBC, but subsequently developed AIHA within a few years.<sup>7</sup>

The treatment of patients with PBC/AIH depends on the dominant type of the liver disease (PBC type or AIH type).<sup>1</sup> Corticosteroids, azathioprine, UDCA and fenofibrate can all be used for treatment.<sup>1,8,9</sup> Patients with AIHA associated with PBC or variant syndrome PBC type respond to UDCA,<sup>8</sup>

but there are reports that the combination of UDCA and fenofibrate can be much more beneficial in PBC.<sup>9</sup>

In conclusion, anemia can coexist with a variety of autoimmune liver disease syndromes.<sup>2-7</sup> These syndromes may lead to cirrhosis, especially if they begin at a young age, and early and effective treatment of these liver diseases may be needed to restore Hb levels.<sup>1,8,9</sup>

## ΠΕΡΙΛΗΨΗ

### Αναιμία που σχετίζεται με αυτοάνοση ηπατοπάθεια σε γυναίκα μέσης ηλικίας

Ν.Δ. ΚΑΡΑΚΟΥΣΗΣ,<sup>1</sup> Β. ΚΟΛΩΝΙΑ,<sup>1</sup> Α.Δ. ΣΑΛΤΑΜΑΥΡΟΣ,<sup>1</sup> Π. ΝΤΕΛΛΑΣ,<sup>2</sup> Κ. ΚΑΛΙΓΕΡΟΣ<sup>1</sup>

<sup>1</sup>Β΄ Παθολογική Κλινική, Γενικό Νοσοκομείο Αθηνών «Σισμανόγλειο», Αθήνα, <sup>2</sup>Μεταπτυχιακό Πρόγραμμα Σπουδών (MSc), Κλινικές Εφαρμογές Μοριακής Ιατρικής, Τμήμα Ανοσολογίας, Ιατρική Σχολή, Πανεπιστήμιο Θεσσαλίας, Λάρισα

Αρχεία Ελληνικής Ιατρικής 2019, 36(1):114–116

Η αυτοάνοση ηπατίτιδα και η πρωτοπαθής χολική χολαγγειίτιδα μπορούν να συνυπάρξουν ως σύνδρομο αλληλοεπικάλυψης. Σε γυναίκα μέσης ηλικίας με αναιμία και ασκτική συλλογή, μετά από κατάλληλο κλινικό και εργαστηριακό έλεγχο, καθώς και ηπατική βιοψία, αναδείχθηκε αυτοάνοση ηπατοπάθεια ως το αίτιο της αναιμίας της. Αυτή η διαπίστωση έρχεται να προστεθεί σε μια σειρά περιπτώσεων στην παγκόσμια βιβλιογραφία συσχέτισης συνδρόμου αλληλοεπικάλυψης με αναιμία.

**Λέξεις ευρητηρίου:** Αυτοάνοση αιμολυτική αναιμία, Αυτοάνοση ηπατίτιδα, Ουρσοδεοξυχολικό οξύ, Πρωτοπαθής χολική χολαγγειίτιδα, Σύνδρομο αλληλοεπικάλυψης

## References

- WEILER-NORMANN C, LOHSE AW. Variant syndromes of autoimmune liver disease: Classification, diagnosis and management. *Dig Dis* 2016, 34:334–339
- EFE C, WAHLIN S, OZASLAN E, BERLOT AH, PURNAK T, MURATORI L ET AL. Autoimmune hepatitis/primary biliary cirrhosis overlap syndrome and associated extrahepatic autoimmune diseases. *Eur J Gastroenterol Hepatol* 2012, 24:531–534
- KORKMAZ H, BUGDADI MS, TEMEL T, DAGLI M, KARABAGLI P. Autoimmune hepatitis-primary biliary cirrhosis overlap syndrome concomitant with immune hemolytic anemia and immune thrombocytopenic purpura (Evans syndrome). *Clin Res Hepatol Gastroenterol* 2013, 37:e45–e50
- DE MEDEIROS CR, SETÚBAL DC. Autoimmune hemolytic anemia as a complication of primary biliary cirrhosis. *Turk J Haematol* 2004, 21:153–155
- GONZALEZ-MORENO EI, MARTINEZ-CABRIALES SA, CRUZ-MORENO MA, BORIAS-ALMAGUER OD, CORTEZ-HERNANDEZ CA, BOSQUES-PADILLA FJ ET AL. Primary biliary cholangitis associated with warm autoimmune hemolytic anemia. *J Dig Dis* 2016, 17:128–131
- TIAN Y, WANG C, LIU JX, WANG HH. Primary biliary cirrhosis-related autoimmune hemolytic anemia: Three case reports and review of the literature. *Case Rep Gastroenterol* 2009, 3:240–247
- RETANA AK, KAPLAN MM, ERBAN JK. Autoimmune hemolytic anemia in patients with liver transplants for primary biliary cirrhosis: Three case reports and a review of the literature. *Am J Gastroenterol* 2007, 102:197–200
- FULLER SJ, KUMAR P, WELTMAN M, WILEY JS. Autoimmune hemolysis associated with primary biliary cirrhosis responding to ursodeoxycholic acid as sole treatment. *Am J Hematol* 2003, 72:31–33
- CHEUNG AC, LAPOINTE-SHAW L, KOWGIER M, MEZA-CARDONA J, HIRSCHFIELD GM, JANSSEN HL ET AL. Combined ursodeoxycholic acid (UDCA) and fenofibrate in primary biliary cholangitis patients with incomplete UDCA response may improve outcomes. *Aliment Pharmacol Ther* 2016, 43:283–293

Corresponding author:

N.D. Karakousis, Second Department of Internal Medicine, "Sismanogleio" General Hospital, 1 Sismanogleiou street, 151 26 Marousi, Greece  
e-mail: karak2727@gmail.com