

CONTINUING MEDICAL EDUCATION ΣΥΝΕΧΙΖΟΜΕΝΗ ΙΑΤΡΙΚΗ ΕΚΠΑΙΔΕΥΣΗ

Pediatric Radiology Quiz – Case 11

A 2½-year-old girl presented to the Emergency Department of our hospital due to sudden enlargement of a known painless swelling in the right upper neck region. Clinical examination revealed a large right neck mass, with local warmth and tenderness. Neck X-ray showed a soft tissue mass with normal appearance of upper respiratory tract (fig. 1). Ultrasound showed a large lesion, of mixed echotexture, with deep cystic component, echogenic areas with intracystic septae (hemorrhagic), that dislocated gently the right carotid artery and the right internal jugular vein (figures 2a, 2b). Imaging findings were consistent with clinical main diagnosis. Magnetic resonance imaging (MRI) of neck was performed in an outpatient diagnostic center, in order to examine the lesion's relations with adjacent deep structures and plan its treatment. Surgical resection was performed and histopathology verified the radiologic main diagnosis.

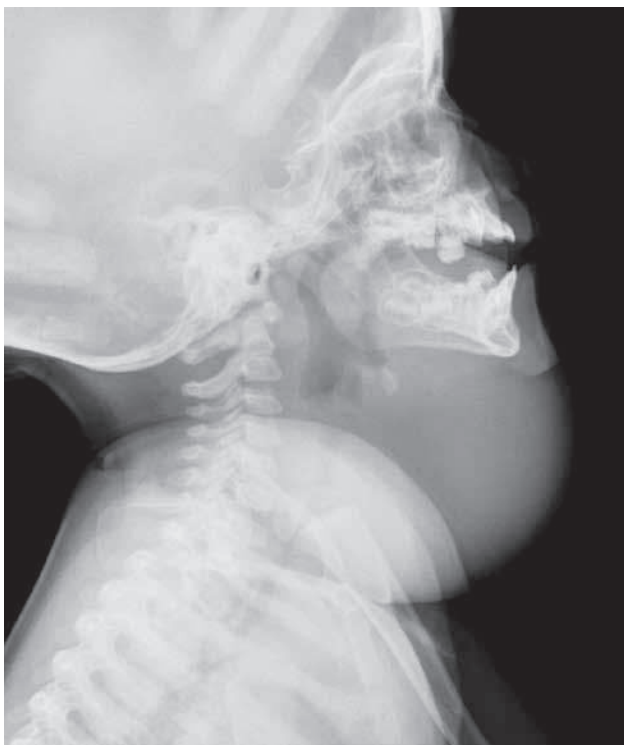

Figure 1. Neck X-ray (lateral view): Soft tissue mass in anterior neck region. Normal imaging of upper respiratory tract.

ARCHIVES OF HELLENIC MEDICINE 2015, 32(1):116–117
ΑΡΧΕΙΑ ΕΛΛΗΝΙΚΗΣ ΙΑΤΡΙΚΗΣ 2015, 32(1):116–117

T.N. Spyridopoulos,¹
K. Velaoras,²
K. Tsilikas,¹
T. Dagla,¹
A. Sakellaropoulos,¹
N. Evlogias¹

¹Department of Radiology, General Children's Hospital, Palea Penteli
²Department of Pediatric Surgery, General Children's Hospital, Palea Penteli, Greece

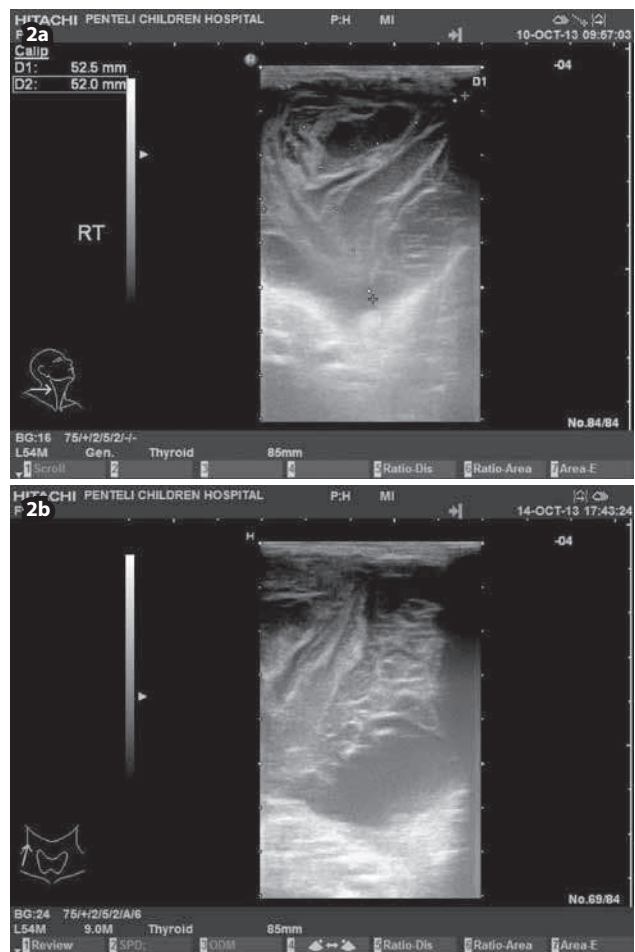


Figure 2a, 2b. Ultrasonography (US) of right posterior neck, showing a lesion with internal septae, hyperechoic internal areas (hemorrhagic) and deep cystic component (a: axial view; b: sagittal view).

Comment

Lymphangiomas are rare, congenital malformations of the lymphatic system. They occur throughout the body (greater frequency in the cervicofacial region), and they are almost all detected before two years of age. Cystic hygromas account for the majority of the lymphangiomas in the head and neck region (approximately 90%). Ultrasonography (US) is the first line imaging method to diagnose and follow up such lesions, in terms of their size and extension to the deep underlying soft tissues. MRI and computed tomography (CT) can be used to define the exact margins of the lesion, examine in detail its deep component, in order to plan its surgical resection. The clinical course of lymphangiomas varies from a spontaneously regressing cyst to an aggressively invasive lesion. Spontaneous or traumatic hemorrhage is their most common complication. Airway

obstruction and infections are other common complications in neck lymphangiomas.

References

1. GRASSO DL, PELIZZO G, ZOCCONI E, SCHLEEF J. Lymphangiomas of the head and neck in children. *Acta Otorhinolaryngol Ital* 2008, 28:17–20

Corresponding author:

T.N. Spyridopoulos, Department of Radiology, General Children's Hospital, Palea Penteli, Greece
e-mail: thspyrid@med.uoa.gr